

Aesthetic reconstruction of the nose following skin cancer

Richard M. Kline, MD^{a,b,*}

^aEast Cooper Plastic Surgery, Suite 120, 1300 Hospital Drive, Mt. Pleasant, SC 29464, USA

^bDivision of Plastic Surgery, Medical University of South Carolina, 171 Ashley Avenue, Charleston, SC 29425, USA

Aesthetic reconstruction of the injured nose makes extensive demands of the plastic surgeon's skill. From its central position in the face, the nose cannot escape the attention of even the casual observer, thus placing a premium on the quality of nasal reconstructions. "Filling the hole," the primary goal in many reconstructive situations, is but one component of a successful nasal reconstruction [1].

Nasal reconstruction does not seek to precisely duplicate missing anatomy, but rather to create a facsimile of the missing part [2]. Ideally, this will sufficiently resemble a normal nose at a conversational distance to escape attention. To accomplish this, surface cover of similar appearance to surrounding skin must be used in the reconstruction, and its contour must be precisely formed to mimic that of the missing part.

Evaluation

Successful nasal reconstruction begins with a meticulous evaluation of the defect. If the defect is not analyzed properly, then little chance exists that it will be reconstructed satisfactorily. Among the questions to be answered are:

1. Which portions of skin cover are missing? The subunits of the dorsum, sidewalls, ala, tip, and columella should be drawn out on every nose presenting for reconstruction, and precise measurements should be made, in millimeters, of how much skin cover is missing from each

involved subunit. Care should be taken to compensate for the effects of skin retraction on the wound borders, which can make a defect appear larger than it really is. Precise reconstruction of a nasal defect begins with precise assessment of the amount of skin replacement needed.

2. What is the depth of the defect? Is the depth of the wound consistent throughout its extent, or does it vary? Shallow defects, particularly those in the upper two thirds of the nose, sometimes may be satisfactorily covered by a full-thickness skin graft. Deeper defects may require flaps, or flaps and structural support. Structural support in the form of grafts is almost never needed in upper one-third defects, often needed in middle one-third defects, and very often needed for proper reconstruction of significant lower one-third defects, particularly those involving the ala.
3. Is the lining intact? If not, how much is missing? Is lining of the alar margin missing, or is the defect more centrally located?
4. Is midline support missing; that is, has a significant portion of the septum been removed?

Once the above assessment is completed, a reconstructive plan is carefully prepared, taking into account all of the information gleaned during the assessment. A few careful moments spent in planning may mean the difference between an enjoyable, successful reconstruction, and a frustrating endeavor with a poor result.

Lining

If lining is missing, its replacement should be the first consideration. Small defects in lining, particularly

* East Cooper Plastic Surgery, Suite 120, 1300 Hospital Drive, Mt. Pleasant, SC 29464.

E-mail addresses: drkline@ecplasticsurgery.com, rmkline@comcast.net

when located centrally in the wound, sometimes may be closed primarily. Knots should be placed in the nasal lumen, not in the wound, if possible. Primary closure becomes a less satisfactory solution as the lining defect gets larger, and as it approaches the alar margin. No tension on the lining of the alar margin can be tolerated, or the resulting reconstruction will be visibly distorted.

Many different sources of lining replacement have been used successfully, including local skin turnover flaps, nasolabial flaps, forehead flaps, and skin-grafted flaps. Turnover flaps from the wound margin may be convenient, and have been used in many successful reconstructions. The surgeon must assess their vascularity carefully, however, because they are frequently at least partly comprised of scar tissue. Forehead or nasolabial flaps used for lining may be well vascularized, but they invariably add unneeded bulk within the nasal airway. Skin-grafted flaps have historically made it difficult to incorporate structure in the form of cartilage grafts. This shortcoming has been circumvented by the three-stage forehead flap, which will be discussed later.

The remaining intranasal mucosa, if adequate, should be the first choice for lining material. The nasal mucosa is richly vascularized, very compliant, and ideally suited to nourish cartilage grafts. Burget [3] has demonstrated that a bipedicle mucosal flap based on the septum and nasal sidewall can reliably supply excellent lining in many nasal defects. Remnants of the lower lateral cartilage may be included with the flap, but may not provide necessary rigidity without additional cartilage grafts. The cephalad border of this flap ideally extends as far under the nasal bone as possible, thus leaving the donor defect where re-epithelialization may occur without producing contraction of adjacent soft tissues. If insufficient vault mucosa exists to bring a bipedicle flap to the alar margin, or if a bipedicle flap is transferred but additional lining is required, then an ipsilateral anteriorly based septal mucoperichondrial flap may be employed [1]. In the event that septal tissue is required for lining, but the ipsilateral septal mucosa is inadequate, then the contralateral septal mucosa may be used. This should be mobilized as a superiorly based hinge flap. Its greatest reach will be realized if it is transferred over the top of the septum, and not passed through a defect made in the septal cartilage.

Although skin-grafted flaps as a source of lining have had the disadvantage of making placement of structural support difficult, Menick's introduction of the three-stage forehead flap [4–6] has circumvented this problem. With this technique, if cartilage grafts are required for structural support, they may be placed

between the revascularized skin grafts and the elevated forehead flap skin at the second stage of the procedure. Using this method, full-thickness grafts may be employed satisfactorily to provide all the lining for any defect, which may be covered with a forehead flap, thus allowing for reconstruction of lining with structural support, even when no intranasal mucosa is available. More commonly, existing vault mucosa will be used for partial lining reconstruction, and any remaining defects will be reconstructed with full-thickness grafts, instead of septal flaps. This confers the potential advantages of less interference with the nasal airway, and less exposure (and possible loss) of septal cartilage.

Occasionally, massive nasal defects may present with essentially total loss of lining and cartilage. In these rare instances, midline support must be established with a cantilevered bone or cartilage graft. Given this scenario, a thin free flap may be the best choice for lining [7]. Its bulk may impinge on the nasal airway, but a more elegant solution may not be readily available.

Structural support

Structural support is commonly provided with cartilage grafts. Upper-third defects do not require additional structural support unless the nasal bone is absent. Middle-third defects may require support, depending on their size and depth. Large tip defects often require cartilage grafts for support. Any attempt to reconstruct a total or subtotal alar defect without structural support will likely result in both an unaesthetic reconstruction and incompetence of the external nasal valve [8].

Septal cartilage, which is usually flat, is particularly useful in middle-third defects. It may be used as a free graft, or as a composite flap with contralateral septal mucosa. Free septal grafts are harvested through a standard submucoperichondrial approach. Care must be taken to leave at least a 1-cm wide "L" strut for dorsal support.

Conchal cartilage, which is curved, is ideal for providing support to alar and tip defects. Usually, a piece of conchal cartilage can be obtained that closely resembles the natural curve of the part to be reconstructed. Conchal cartilage is readily harvested through an incision on the posterior conchal skin. Prior injection of epinephrine into the concha on its anterior and posterior surfaces greatly facilitates the dissection. All of the conchal cartilage may be removed without producing a cosmetic deformity as long as the antihelix, the antitragus, and the root of the

helix are left intact. It is helpful to pass a 30-gauge needle through the anterior surface of the concha adjacent to these landmarks during the dissection, using the points of exit of the needle on the posterior surface of the cartilage as a guide to the margins of resection. With practice, an intact dumbbell-shaped piece of cartilage 3 to 4 cm in length and 1 to 2 cm in width can be obtained expeditiously. A petrolatum gauze bolster, which is sewn into the anterior concha for several days, helps ensure hemostasis, as well as even distribution of loose conchal skin.

Extra time spent carefully contouring and shaping a cartilage graft is usually well invested. Cartilage grafts should generally be made slightly smaller than the overlying skin defect. The graft should be coated gently to the underlying lining with fine absorbable sutures, with knots placed in the nasal lumen. Whenever possible, sutures used to secure cartilage should be on tapered needles, because cutting needles can induce delicate grafts to fracture.

Significant loss of the septum, resulting in loss of midline support, requires different methods of restoration than does a structural loss to the tip, the ala, or the sidewall. For septal defects of several millimeters, onlay grafts may be sufficient to restore dorsal support. For defects of 1 to 2 cm, the septum may be mobilized as an L-shaped chondromucoperichondrial flap, based either superiorly or inferiorly (depending on the location of the defect) and rotated anteriorly to supply dorsal midline support [9]. The blood supply of this composite flap is preserved via its mucosal attachment or “hinge.” If insufficient septum exists to provide dorsal support with a composite chondromucoperichondrial flap, then an L strut of bone or cartilage may be used. Lacking a blood supply, this will require separate lining to nourish it. Similarly, a cantilever graft of rib or cranial bone may be employed.

Skin cover

Skin cover is the last tissue to be replaced in nasal reconstruction (excluding some instances of the three-stage forehead flap). Skin used to resurface the nose should resemble nasal skin as much as possible. The replacement skin, whether grafts or flaps, also should be supplied with sufficient thickness to create the appropriate contour, or should be applied on top of grafts or flaps of sufficient thickness.

Skin grafts are suitable for reconstruction of some defects [10]. Skin grafts tend to develop a flat surface as healing progresses, and therefore work best for the upper two thirds of the nose, where the nasal skin is

thinner and contours are flatter [7]. Small areas of exposed cartilage usually will not interfere with graft survival, because the graft will revascularize from tissue peripheral to the cartilage. Full-thickness grafts more closely resemble normal skin and contract less than split-thickness grafts. The preferred donor site for full-thickness grafts to the nose is the preauricular area [2]. The postauricular and supraclavicular areas also may be useful. When applying skin grafts, meticulous hemostasis must be achieved in the recipient bed, and a gently compressive bolus dressing should be applied for several days. Open treatment of the graft is another option, but then the potentially beneficial effects of compression on postoperative hemostasis are lost.

Chondrocaneous grafts, generally harvested from the helical crus, have been advocated for reconstruction of full-thickness alar defects [11]. These have the primary advantages of simplicity because all three layers of the defect are replaced from one source, and of not disturbing surrounding nasal structures. Although some [11] have demonstrated good results with this technique, the skin is not as good a match for nasal skin as is that from forehead flaps or nasolabial flaps. Additionally, graft survival may become tenuous as the size of the defect increases.

Flaps can provide skin that more closely matches nasal skin than do grafts. Many types of flaps have been employed successfully in nasal reconstruction, and few absolutes exist in deciding what type of flap to use in what situation. However, some specific flaps have proved to be both reliable and capable of producing good cosmetic results in many situations.

Cheek flaps have long been advocated for reconstruction of alar and sidewall defects [12]. Two-stage transposition flaps in the form of nasolabial flaps for alar reconstruction are discussed below. One-stage cheek transposition flaps have also been advocated for reconstruction of the ala and sidewall [11]. These frequently result in an unnatural appearance, however, and appropriate subunit definition may not be achievable in one stage [12]. Subcutaneous pedicle flaps from the cheek have been used in the reconstruction of nasal defects [11,13]. Although these may appear to provide an acceptable one-stage solution in some circumstances, prolonged edema and “pincushioning” may be a persistent problem. Advancement cheek flaps, however, work well for reconstruction of sidewall defects, and may decrease the size of very large defects to more manageable dimensions. Advancement cheek flaps are developed by extending an incision from the superior aspect of a nasal defect laterally into a prominent infraorbital crease. Undermining then is performed in the facelift plane until sufficient laxity is achieved. A small Burrow’s trian-

gle may need to be excised medially, parallel to the nasolabial crease. Advancement of these flaps is readily maintained by sutures anchored to underlying bone or cartilage, or by transnasal sutures.

The bilobed flap can provide good skin cover in a wide range of partial-thickness defects of the nose [7,14]. Because it uses nasal skin, it provides the best possible color match for acceptable-sized defects. Additionally, because it employs a relatively wide base, it rarely develops pincushioning or edema when healing is complete. Recommendations for the maximum size defect amenable to reconstruction with this flap range from 1.5 to 2.0 cm. In practice, variables such as the size of the individual's nose, the amount of skin laxity present, and the precise location of the defect determine whether this flap should be used in a given situation. The bilobed flap may be based medially or laterally, depending on the location of the defect. Proper geometric planning of the bilobed flap is essential to its successful use. The lobe nearest the defect should be almost exactly the size of the defect, whereas the second lobe may be somewhat narrower. A Burrow's triangle should be excised proximal to the defect, and another should be excised at the distal aspect of the secondary lobe. The axis of the defect and the secondary lobe should not exceed 100 degrees, or an excessive dog-ear will result. Considerable flexibility in the orientation of the flap may appear to be present, but careful study of available skin laxity and proximity of sensitive landmarks (lower eyelid, alar margin) usually shows one specific orientation to be the best. Wide undermining of all nose and cheek skin surrounding the flap and the defect at the level of the perichondrium or periosteum often is necessary to achieve a closure with acceptable tension. If the original wound was very large, tension on the flap may be reduced by suturing the subcutaneous tissues of the wound borders to underlying cartilage or periosteum prior to flap insetting. The flap itself is usually best inset with skin sutures alone. Skin adjacent to landmarks that should not be distorted, such as the eyelid and alar margin, should never be undermined. With this in mind, the bilobed flap becomes more difficult to use successfully as the defect or the required donor site approaches these landmarks.

The superiorly based nasolabial flap is well suited for the reconstruction of an entire alar subunit [2,8]. It may be more useful for those patients who have thicker, fleshier ala. For optimum results, it must be used as a two-stage flap. The contralateral ala should be used as a template from which to fashion the pattern for the new ala. Any reconstruction of an entire ala should include a cartilage graft for support [15]. If this

is omitted, the aesthetic result likely be compromised and the patient may have difficulty breathing due to inspiratory collapse of the inadequately supported alar reconstruction. The flap, which is based on perforating branches of the facial artery, is always elevated with its medial border directly in the nasolabial groove. The flap should be thinned at the time of transfer to provide the exact thickness desired in the inset portion. Division and proximal inset then should be performed 3 weeks later. Careful study of the form and dimensions of the contralateral normal subunit should be performed again at the second stage, because the noninset portion of the flap may have healed and contracted considerably in the intervening 3 weeks. All of the unused flap should be excised from the donor site adjacent to the nasolabial groove, and the donor site closed as a line. After division and inset, the nasolabial flap will swell to a size considerably larger than that to which it was originally thinned. With patience, however, the edema usually will subside over a period of months, leaving most properly sculpted flaps very much resembling normal ala. Nasolabial flaps also may be used to reconstruct isolated defects of the columella [16], although columellar defects contiguous with tip defects may be better reconstructed with a forehead flap.

The paramedian forehead flap is the true workhorse in nasal skin replacement. Based on the supra-trochlear artery and angular arteries, it can reliably carry a large paddle of skin to resurface the tip of the nose. Forehead skin resembles nose skin more than any other donor area. In fact, because forehead skin usually sustains less sun damage than nasal skin, a forehead flap transferred to the nose actually may look even better than the rest of the nose. The forehead flap can be made very thin and supple, as long as care is taken to preserve the dermal vessels in the thinned portion. The forehead flap undoubtedly offers the best tissue to replace a full-thickness defect of the entire nasal tip [2]. Larger areas also can be covered, especially if the donor site does not require primary closure. Because it can be thinned much more aggressively than a nasolabial flap, the forehead flap also is useful in reconstructing thin-walled alar defects. It works very well in reconstructing defects of the dorsum and sidewalls, but consideration should be given to reserving it for cases in which no other suitable coverage options exist. Patients with a history of skin cancer have a significant risk of developing additional skin cancers. Although it is true that multiple forehead flaps often can be elevated safely in the same patient, it only makes sense to save the forehead flap for lesions that cannot be as well reconstructed by other means.

Once a decision is made to use a forehead flap, a good place to begin is Doppler location of the supra-trochlear artery. It has been demonstrated that the flap is capable of surviving on the angular vessels alone [17]. Nonetheless, attempted preservation of the supratrochlear vessels is a prudent approach. The base of the flap should be at least 1.2 to 1.5 cm in width [2]. It then should extend directly up the forehead until sufficient length is obtained to reach the most inferior portion of the nasal defect. Although some [8] advocate angling the tip of the flap laterally if a low hairline is present, continuing it directly into the hairline may be a safer option. An angled flap cannot use all of its length without straightening out the angled portion, which then creates a choke point for the blood supply. If hair follicles at the tip of a flap cannot be removed successfully during thinning, then a hair-removal laser or electrolysis can be used after healing is completed.

The flap should be elevated at the subfrontalis or subgaleal level throughout its length if primary closure is planned, because this makes closure more straightforward. If the surgical plan includes leaving an open wound to granulate closed, then elevation of the distal flap only to the depth necessary for reconstruction is the preferred approach. As the dissection nears the supratrochlear vessels, the subperiosteal plane is entered, thus minimizing the chance of damaging this pedicle. The medial and lateral incisions (especially the medial) then are extended inferiorly until the tip of the flap covers the defect with little or no tension. The end of the flap should be thinned carefully to the precise thickness required to achieve the desired contour. Usually only skin sutures are required for inseting. Fully adequate mobilization of the flap to eliminate tension significantly improves the accuracy with which inseting may be performed. The forehead and scalp are widely undermined after the flap is elevated, and usually closed primarily. Wounds that cannot be closed primarily may be covered with petrolatum gauze and left to granulate, often with a surprisingly good cosmetic result [4]. The open portion of the flap pedicle may be skin grafted, but coverage with a single sheet of methylcellulose is a much easier, and equally effective, solution.

The pedicle usually is divided 3 weeks later. The distal portion is contoured carefully and inset without tension. The proximal portion of the pedicle, if replaced on the forehead, may result in a noticeable and unattractive inverted “V.” Another option is to amputate the remainder of the pedicle and close the remaining donor site wound as a vertical linear scar. Although the medial border of the eyebrow may be

distracted slightly, this may be more aesthetic than is a pedicle replaced superior to the brow.

The three-stage forehead flap, introduced and popularized by Menick [4–6], offers a number of advantages over the traditional two-stage flap. First, all lining can be supplied, if necessary, by skin grafts applied to the forehead flap, or by the flap doubled over on itself. The most distal few millimeters of the flap, which will not be re-elevated at the second stage, is thinned as necessary for inseting. The remainder of the flap is left full thickness, with either the skin graft applied to its undersurface or the tip of the flap folded over on its undersurface. Three weeks later, at the second stage, the skin of the flap is re-elevated as a bipedicle flap at a thickness of about 3 mm, leaving the most distal portion still attached to the nose. The previously placed skin grafts now are revascularized from their periphery, and the subcutaneous tissue and muscle may be thinned and contoured as needed. Cartilage grafts may be placed and then covered with the elevated flap skin. Quilting sutures may be applied to coapt the flap to the underlying framework. Three weeks later, at the third stage, the flap pedicle is divided, and final inseting is performed. Although this method takes twice as long to complete as the traditional forehead flap, it enables the surgeon to provide lining and structural support with only one flap.

Formulating a plan

The reconstructive plan chosen by the surgeon must incorporate the above-mentioned or other techniques in a coordinated fashion. There are few absolute rules for this, but some generalizations may be helpful. If lining can be supplied by residual nasal vault mucosa—that is, a bipedicle mucosal flap—then this affords the most straightforward solution. If this is inadequate, then an ipsilateral septal pivot flap or a contralateral septal hinge flap traditionally would be the next choice. Today, however, serious consideration should be given in this instance to using a three-stage forehead flap, and replacing additional missing lining with skin grafts. The surgeon may wish to discuss with the patient preoperatively the alternatives of using only intranasal tissue for lining (with potentially delayed healing and airway compromise) versus using the three-stage forehead flap (with additional total time required for completion).

Skin cover, whether from grafts or flaps, should be appropriate in color, texture, and thickness. Skin cover also should be planned after considering the nasal subunits. Burget and Menick [2] list the subunits

that should be taken into consideration in nasal reconstruction—these are the dorsum, the sidewalls, the ala, the soft triangles, and the tip. The subunits are defined by areas of contour transition, where the character of reflected light changes. Scars placed within these areas of transition tend to be less noticeable than are scars traversing the central portion of a subunit. If it is not possible to place scars within these transition areas, care still must be taken to duplicate the normal nasal shape as precisely as possible, which will result in light reflections mimicking those of a normal nose.

All of the nasal subunits of the nose should be drawn. Once the subunits are visualized, every effort should be made to devise a skin cover reconstructive plan that is “respectful” of the subunits involved. There are several guidelines to help accomplish this. It has been suggested that a defect occupying less than 50% of a given subunit should simply be “patched” with appropriate skin cover [2]. If a flap is to be used, cartilage grafts still may be required under the flap to preserve shape and structural integrity. If a subunit involves more than 50% of a subunit, Burget and Menick [2] recommend excising the remainder of the subunit and replacing its entire cover as one unit. Although this technique may be employed satisfactorily with wounds involving one or even two subunits, it becomes progressively more difficult, from a practical standpoint, with larger wounds involving greater than 50% portions of multiple subunits. In this situation, one flap may not be sufficiently large to cover the entire wound. One solution to this problem is to employ two or more flaps, with each flap reconstructing one subunit. Another solution is to use one flap to reconstruct portions of multiple subunits, “patching” the defects as they exist, but defining boundaries between subunits with underlying cartilage grafts. Although it is desirable to have all scars lie between subunits, this is but one potential factor determining the acceptability of a final result [18]. A reconstruction that has fine scars crossing subunit boundaries but precisely duplicates the desired shape or form of the reconstructed part will look far better than a reconstruction that has scars placed neatly between subunits, but has not accurately reproduced the desired shape.

Subunit boundaries or contour deformities that cannot be defined easily or safely at the time of flap inset often may be created safely at later surgeries [2]. One commonly occurring example is the delayed creation of an alar crease, when one flap is used to reconstruct portions of an ala and a sidewall or tip. Several months after the flap is divided and inset, it may be divided again at the desired location of the alar

crease, taking care to make this incision as symmetrical as possible with the contralateral alar crease. After an appropriate amount of subcutaneous tissue is excised beneath the incision, the wound is closed with full-thickness polypropylene sutures passed into the nasal cavity and out again, with the knots tied on the exterior skin. These may be left in place for several days and then removed.

Persistent late subcutaneous hypertrophic scarring and edema occasionally compromise what otherwise would be a good aesthetic result. This can be very frustrating to deal with, because simple debulking of the hypertrophic tissue often is followed by recurrence of the original problem. Radical thinning and aggressive use of plicating mattress sutures may be of some help. In refractory cases, the injection of a small amount of triamcinolone directly into the hypertrophic area sometimes is followed by acceptable atrophy. Unfortunately, it is difficult to predict the response that will be obtained with this method.

Radiation

Postexcision radiation may be a useful adjunct in the management of some aggressive skin cancers. When it is possible to do so without affecting the cure rate, radiation should be delayed until after the reconstruction is completed. Although some damage to the reconstruction may occur secondary to the radiation, it probably is more difficult for a surgeon to perform reconstruction in a radiated field than it is for a completed reconstruction to remain reasonably intact through a course of radiation. In the rare post-skin cancer reconstruction in which free tissue transfer is planned, it may be preferable to complete the radiation prior to initiating the reconstruction. When a reconstruction with pedicle flaps or grafts must be performed in radiated tissue, extra care should be taken. Small amounts of tension that would cause no problem in healthy tissue may prevent satisfactory healing in a radiated wound. Preoperative hyperbaric oxygen treatment may be a useful adjunct in some cases [19]. Prudence also may dictate delay in the timing of flap pedicle division.

Secondary reconstructions

Repeat reconstruction, typically required when a cancer has recurred, is rarely as straightforward as the first attempt. Obviously, recurrences are best prevented, and this is a strong argument for routine referral of facial skin cancers to a Mohs' surgeon.

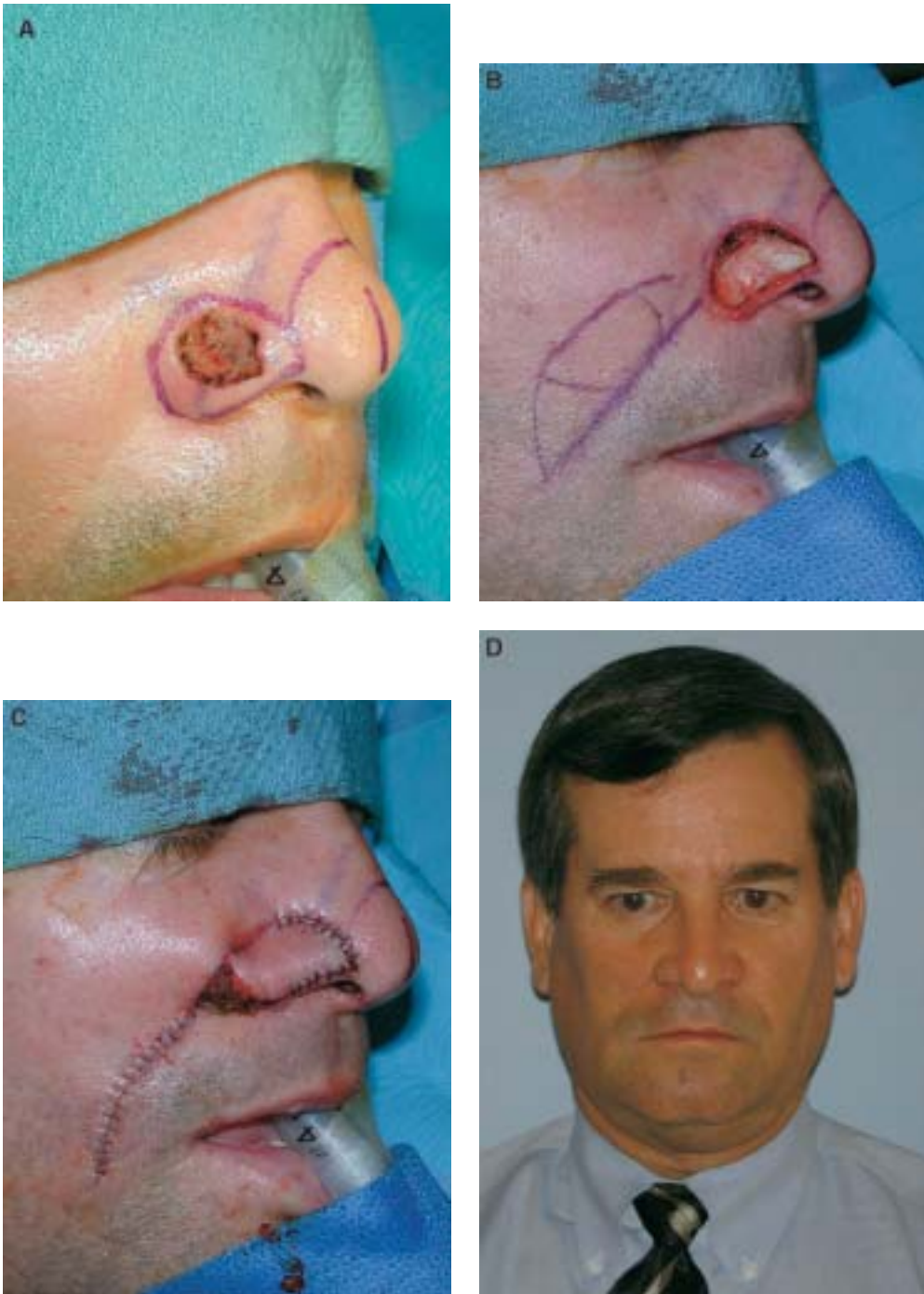

Fig. 1. Reconstruction of an alar defect with a nasolabial flap. (A) Original defect with subunits outlined. No lining defect is present. (B) Remainder of alar subunit has been excised, and conchal cartilage graft has been prepared and secured. Note sketch of planned nasolabial flap. (C) Flap has been elevated and initial inseting performed. (D) Frontal view 3 months following division of pedicle and final inseting. (E) Oblique view at 3 months. (F) Worm's eye view at 3 months. Some edema still is present at this relatively early stage.

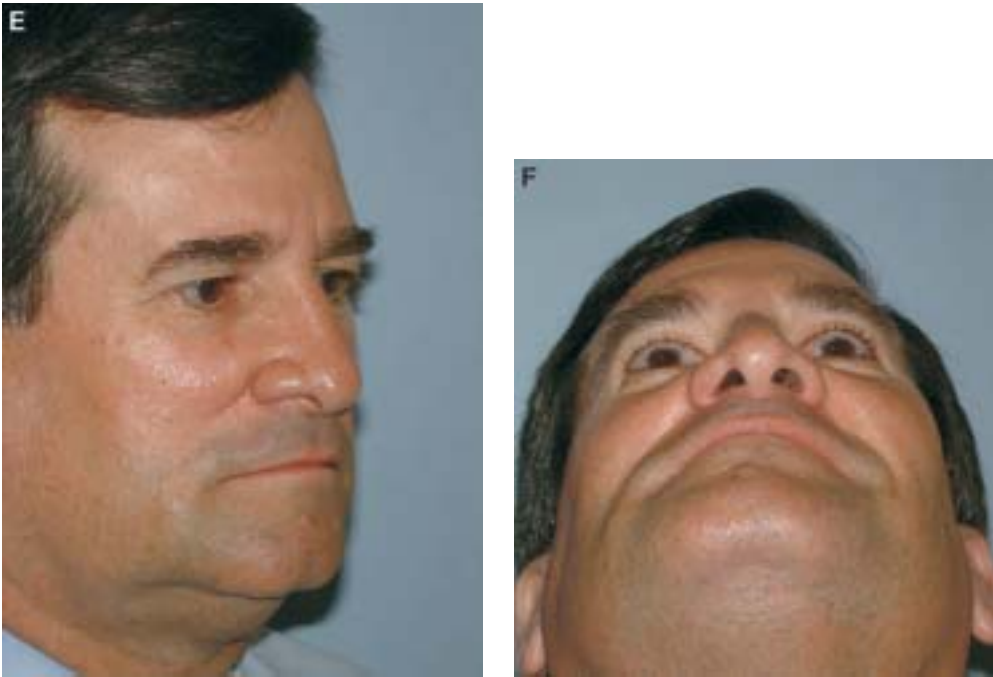

Fig. 1 (continued).

When repeat surgery is required, all the above principles still apply, but decreased availability of local flaps may be a problem. It may be necessary to use second-line flaps in some situations—for example, a nasolabial flap may be used in a defect that ordinarily would be reconstructed with a bilobed flap, were enough nasal skin still present. Repeat forehead flaps usually can be performed in the same patient. Cartilage grafts may be obtained from ribs, if all septal and auricular sites are exhausted. In the absence of available nasal mucosa, lining may be provided with skin grafts and a three-stage forehead flap. Nevertheless, the final reconstruction still may entail some evidence of compromise.

Case studies

The following case studies illustrate many of the techniques discussed in the preceding text.

Case 1

A 55-year-old patient presented with a subtotal defect of the ala. Lining was found to be intact. The remainder of the alar subunit skin was excised. A conchal cartilage graft slightly smaller than the defect

was prepared and then secured within the wound. Skin cover was provided with a nasolabial flap. The dimensions of the flap were carefully planned to match precisely the contralateral normal ala. The flap was divided and inset 3 weeks later. Three months postoperatively, some residual edema persists, but no further surgery is anticipated (Fig. 1).

Case 2

A 49-year-old woman presented with a 15-mm × 20-mm shallow defect of the nasal sidewall and ala. The wound was reconstructed with a medially based bilobed flap. Secondary creation of the alar crease and revision of the dog-ear was performed 8 months later. Although a scar crosses the alar subunit, no additional surgery has been required (Fig. 2).

Case 3

A 53-year-old woman presented with a full-thickness defect of the right tip and ala. A forehead flap was suggested as likely to provide the best aesthetic result, but this seemed to her an extreme solution for a small defect. The lining was reconstructed with a nasal mucosal bipedicle flap, and a septal cartilage graft was placed for support. Skin cover then was provided

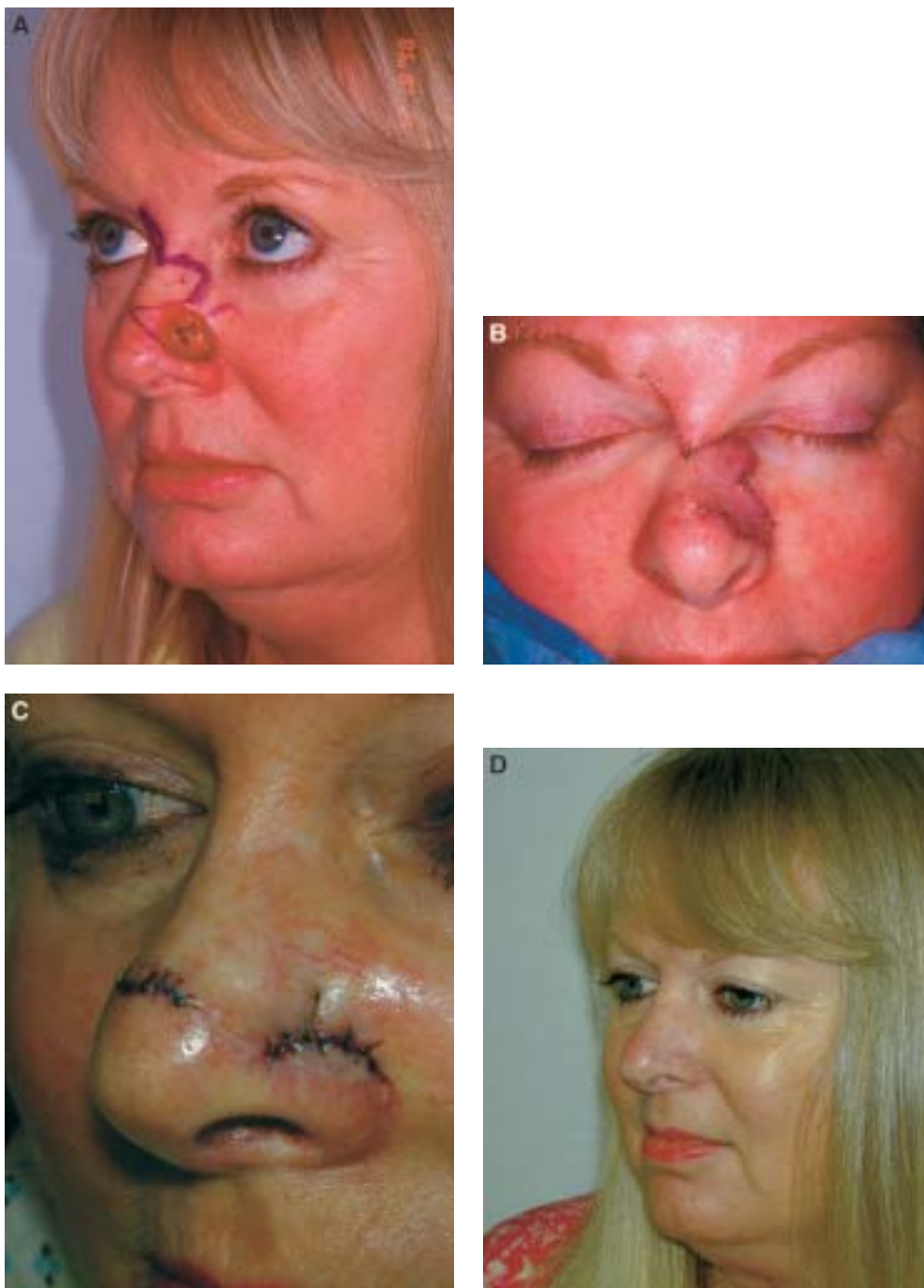

Fig. 2. Reconstruction of a large nasal defect with a bilobed flap. (A) The 15-mm \times 20-mm defect comprises portions of the ala and sidewall. No lining defect is present. A medially based bilobed flap is designed, taking care to avoid distorting landmarks of the eyelids and alar margin. (B) The flap is elevated and inset. (C) Eight months following the initial flap, a secondary procedure is performed to establish the boundary between the ala and sidewall subunits. A small dog-ear also is revised. (D) Six weeks following secondary procedure.

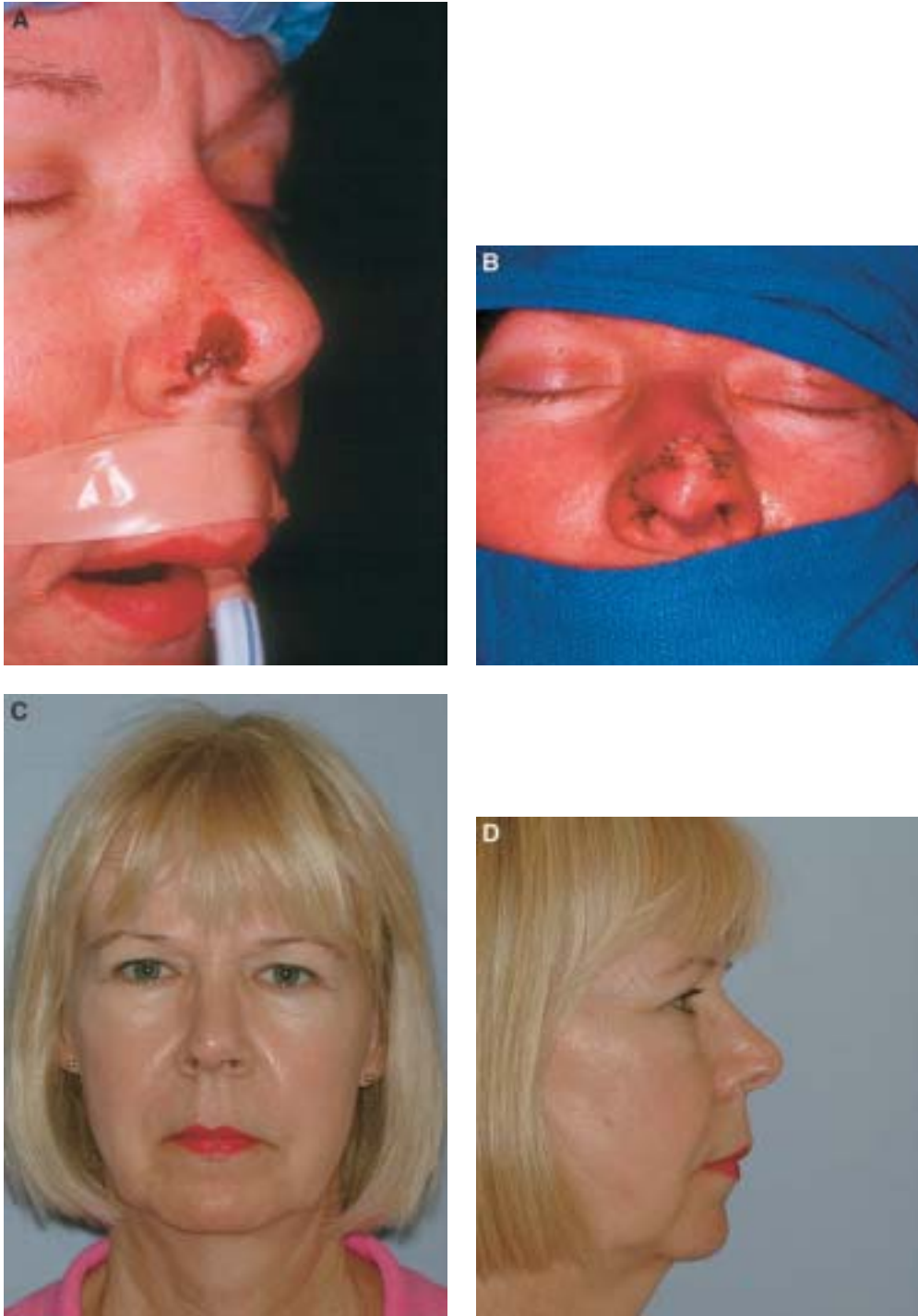

Fig. 3. Reconstruction of a full-thickness alar margin defect with a bilobed flap. (A) Full-thickness defect of ala. (B) Defect reconstructed with bipedicle mucosal flap, septal cartilage graft, and bilobed flap from nasal tip. (C) Four years following one minor surgical revision and laser ablation of telangiectatic vessels of flap. Some residual distortion is noted. (D) Lateral view at four years.

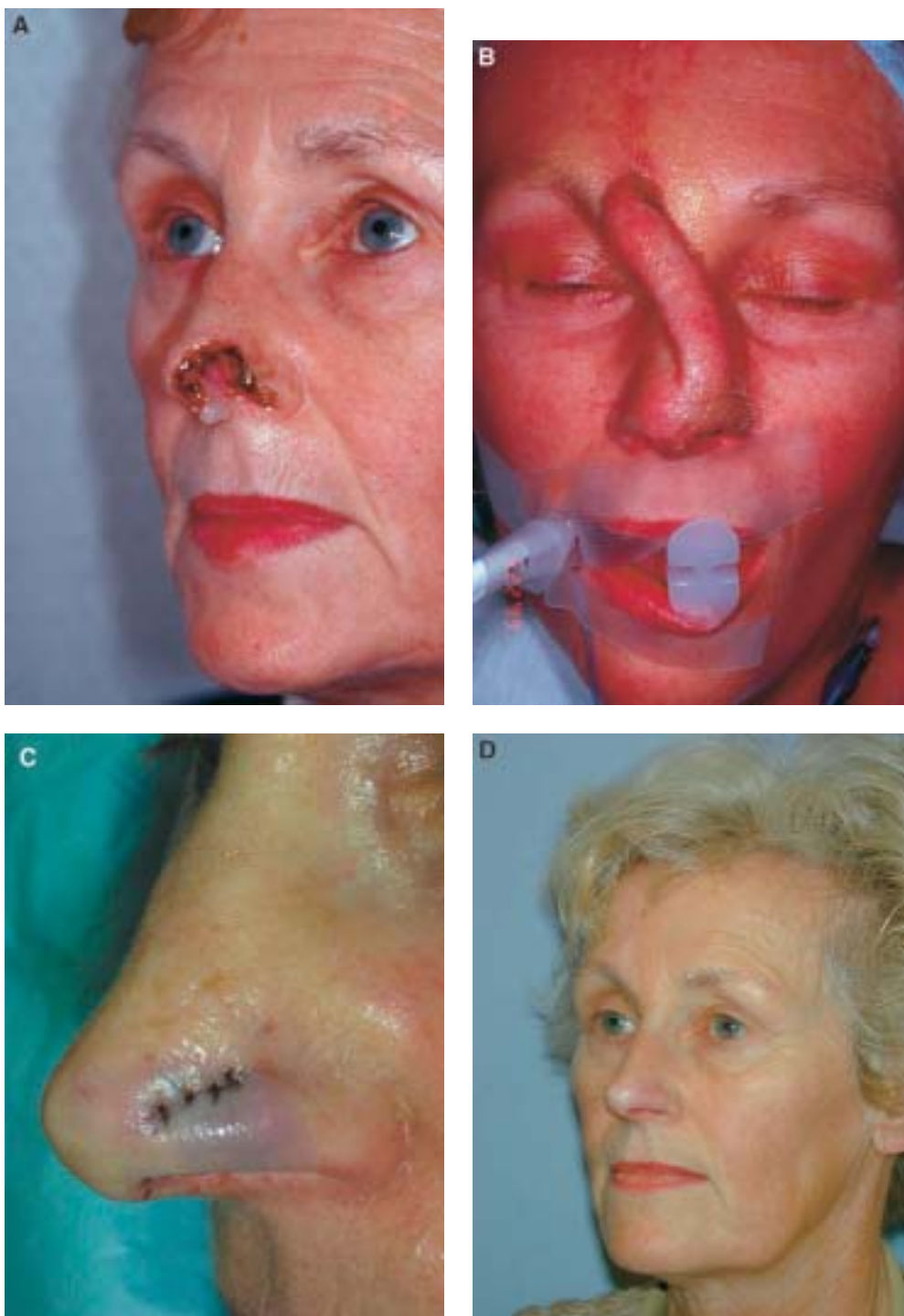

Fig. 4. Reconstruction of full-thickness defect of ala and tip with forehead flap. (A) Full-thickness defect comprising major portions of tip and alar subunits. (B) Reconstruction with bipedicle muosal flap, conchal cartilage graft, and paramedian forehead flap. (C) Delayed creation of alar groove 5 months following division and inset of forehead flap. (D) Six months following completed reconstruction.

with a medially based bilobed flap rotated from the nasal tip. Postoperatively, distortion of the tip was noted. The bilobed flap was revised after 2 months, and an additional cartilage graft from the auricular concha was added at that time. Five years postoperatively, some residual distortion of the tip persists, but the patient remains pleased (Fig. 3).

Case 4

A 61-year-old patient presented with a full-thickness defect of the nasal tip and ala. Lining was provided with a bipedicle flap of nasal mucosa. Conchal cartilage grafts were used to provide support for the tip and alar defects. Cover was provided with a paramedian forehead flap. The flap was divided and inset 3 weeks postoperatively, and delayed creation of the alar crease was performed 5 months later. No further surgery has been required (Fig. 4).

Case 5

A 66-year-old man presented from the Mohs' surgeon with defects of the forehead, nasal tip, left ala, and left sidewall. Nasal lining was found to be intact. The remainder of the skin of the nasal tip subunit was excised and then covered with a paramedian forehead flap. No additional skin was excised from the combined ala/sidewall wound. A conchal cartilage graft was placed in the alar portion of the ala/sidewall wound to provide both alar support and appropriate contour. The forehead wounds were joined and then closed with a scalp flap. Three weeks postoperatively, both the forehead flap and nasolabial flaps were divided and inset. No further surgery was required to define the left alar crease, despite the fact that the ala and sidewall were reconstructed with one flap, because the underlying cartilage graft provided the correct contour (Fig. 5).

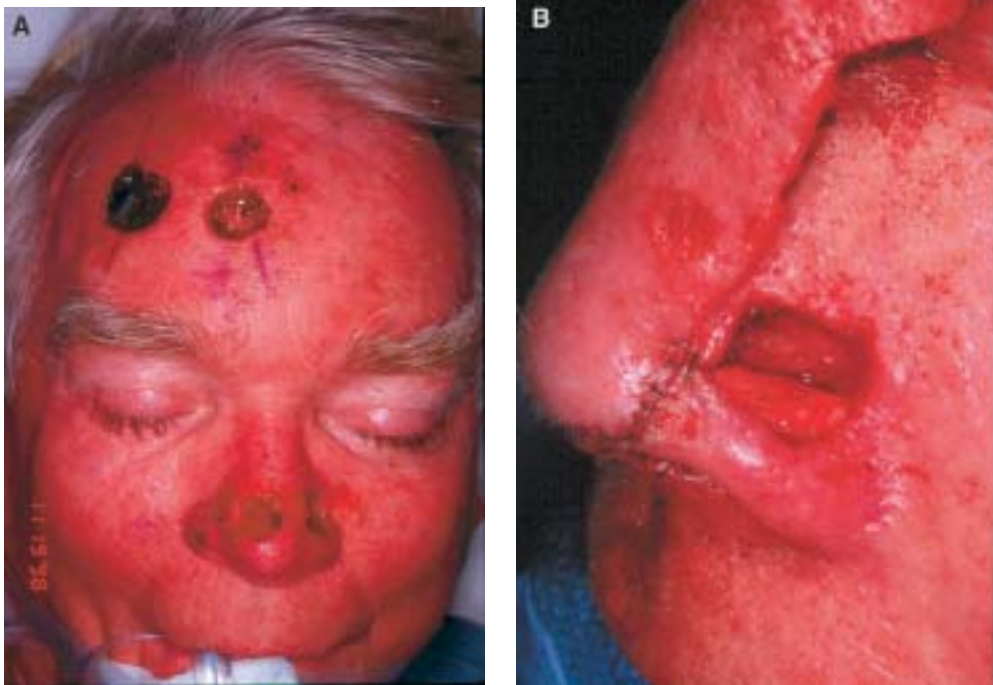


Fig. 5. Reconstruction of defects of tip, ala, sidewall, and forehead with paramedian forehead flap, nasolabial flap, cartilage graft, and scalp flap. (A) Defects of nasal tip, ala, sidewall, and forehead. No nasal lining defects are present. (B) Initial procedure. The forehead flap has been inset. A conchal cartilage graft has been placed within the alar portion of the combined ala/sidewall wound. This will serve to preserve the boundary between these two subunits in the completed reconstruction. (C) Forehead flap and nasolabial flap following initial procedure. Note that a forehead flap was harvested easily despite the pre-existing forehead wounds, which were closed with a scalp flap. (D) Frontal view, 2 years following completed reconstruction. (E) Lateral view, 2 years following completed reconstruction. Note the well-defined border between the reconstructed ala and sidewall, due to the underlying cartilage graft.

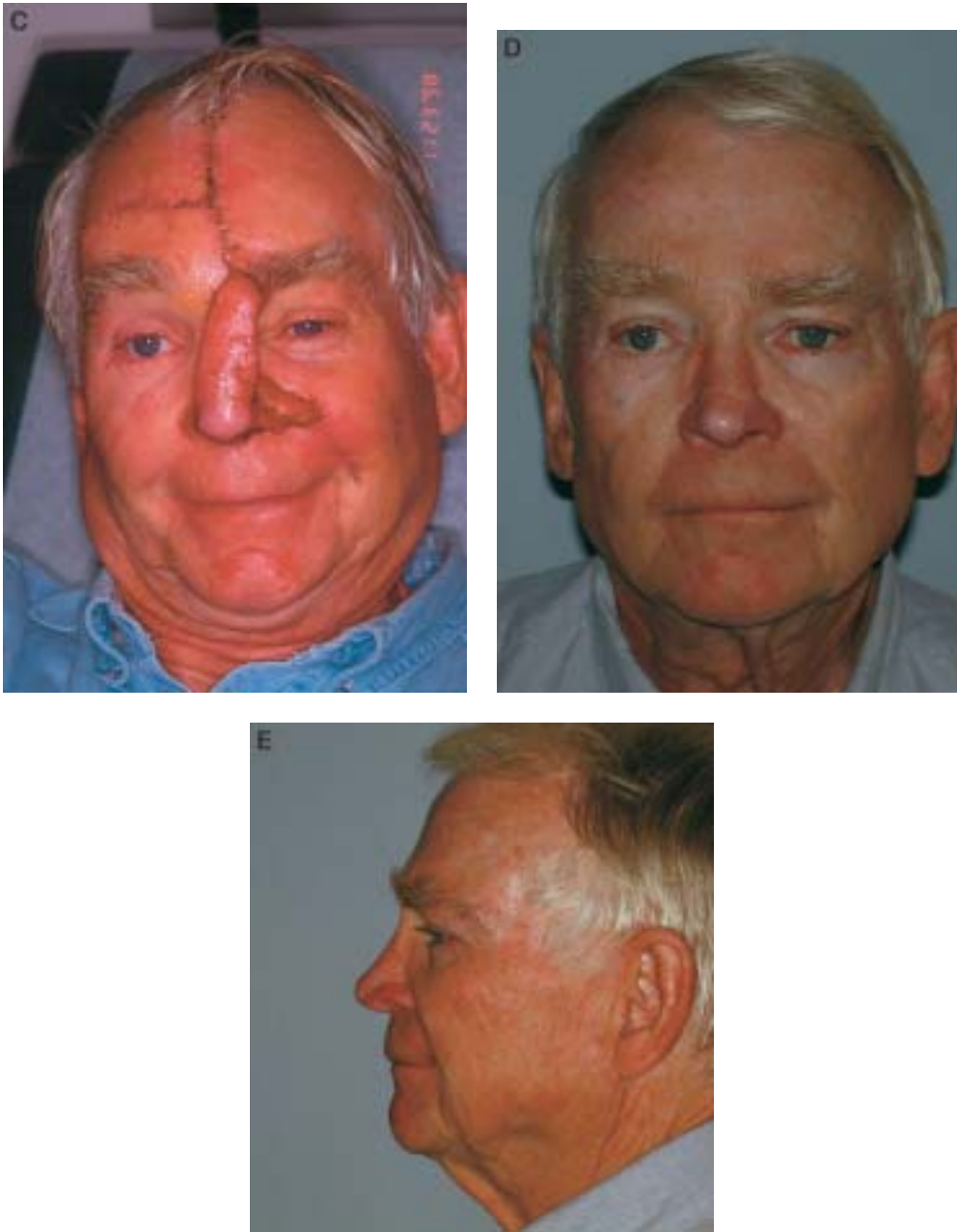

Fig. 5 (continued).

Case 6

A 57-year-old man presented with a healed wound following Mohs' excision of a cancer of the nasal tip and columella. The nasal lining was reconstructed with bilateral bipedicle nasal mucosal flaps. The

structural support to the tip was re-established with a combination of cartilage grafts from the septum and the auricular concha. A paramedian forehead flap then was used to provide skin cover. The forehead flap was divided and inset 3 weeks later. No additional surgery was performed (Fig. 6).

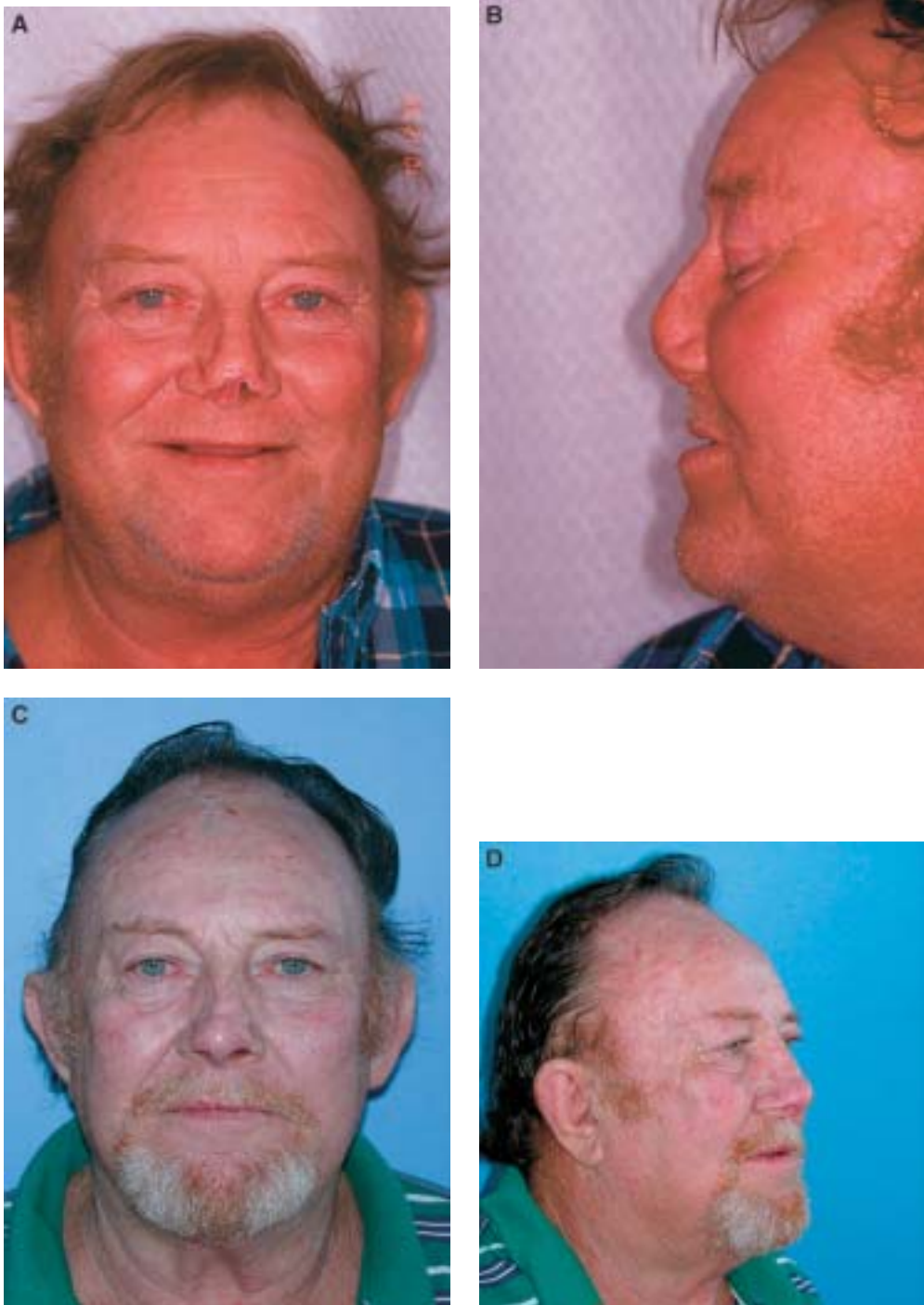

Fig. 6. Delayed reconstruction of total nasal tip defect with paramedian forehead flap, bilateral mucosal flaps, and septal and conchal cartilage grafts. (A) Preoperative frontal view. Patient previously underwent Mohs' resection. (B) Preoperative lateral view. (C) Frontal view, 4 years following reconstruction. (D) Lateral postoperative view.

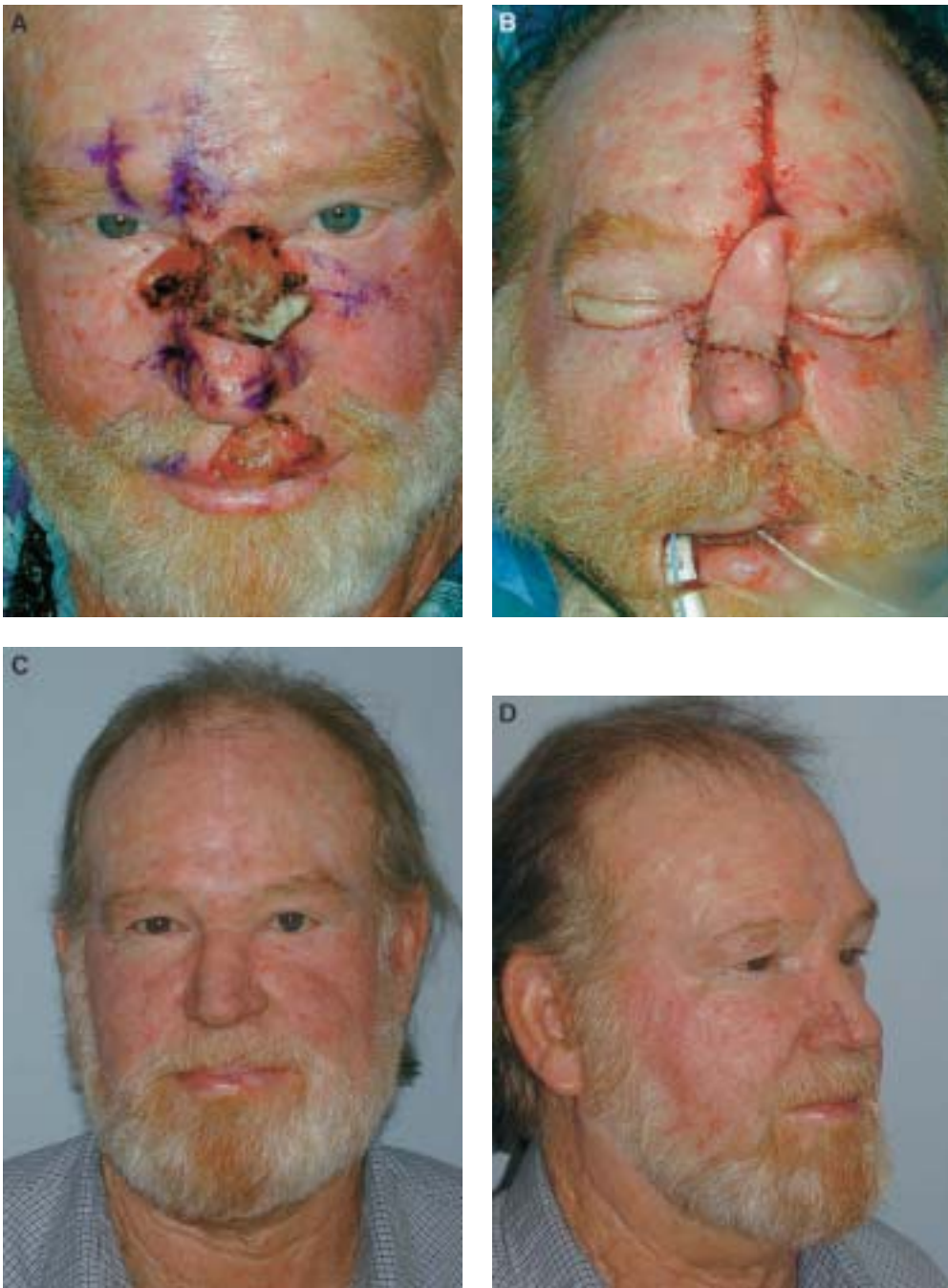

Fig. 7. Reconstruction of nasal and cheek defects. (A) Preoperative frontal view of combined nasal and cheek wounds. A partial-thickness lip wound also is present. (B) The nasal dorsal wound has been covered with a paramedian forehead flap. The nasal sidewall wounds and cheek wounds have been covered with bilateral cheek advancement flaps. The tips of the cheek flaps are secured to the medial canthal regions with transnasal sutures. The lip wound has been converted to a full-thickness wound and closed primarily. (C) Three years following completed reconstruction. (D) Oblique postoperative view.

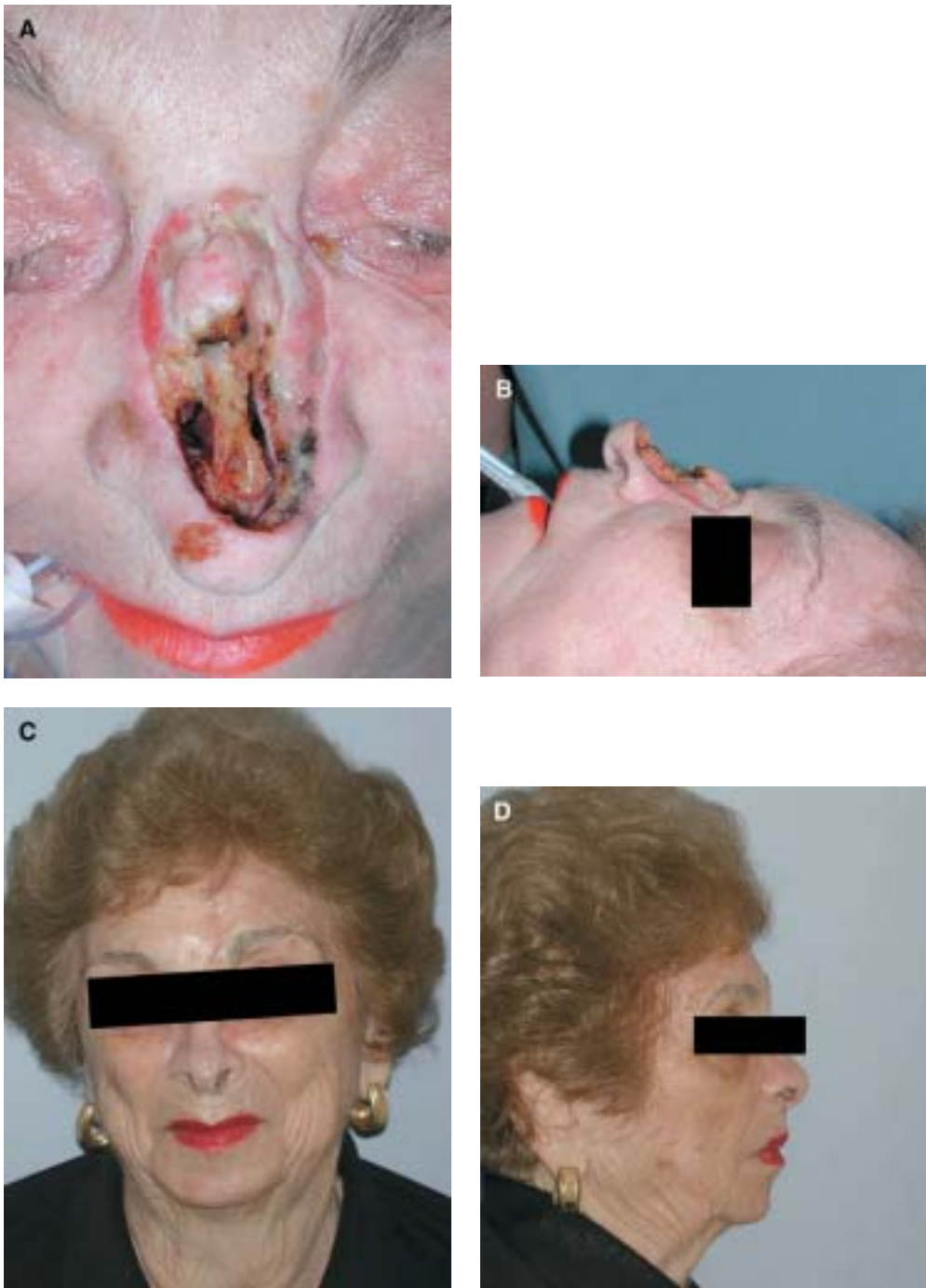


Fig. 8. Reconstruction of a subtotal nasal wound with a three-stage forehead flap, bilateral cheek advancement flaps, conchal cartilage grafts, a hinged septal flap, and postauricular skin grafts. (A) Preoperative frontal view. (B) Preoperative lateral view. (C) Three weeks following division and inset of three-stage forehead flap. (D) Postoperative lateral view.

Case 7

A 60-year-old man presented from the Mohs' surgeon with defects of the nasal dorsum, nasal sidewalls, cheeks, and upper lip. Lining and structural support of the nasal wound were found to be intact. Bilateral cheek advancement flaps were mobilized and then advanced medially to reconstruct the cheeks and portions of the sidewall defects. A 2-0 vicryl suture passed transnasally in the region of the medial canthus was used to secure the apices of the cheek flaps to this location. A paramedian forehead flap then was used to reconstruct the dorsal and remaining sidewall defects. Because the patient customarily wore a beard and mustache, the partial-thickness lip defect was simply converted to a full-thickness defect and then closed primarily. The forehead flap was divided and inset 3 weeks postoperatively. Four years postoperatively, the patient has required no further surgery (Fig. 7).

Case 8

An 81-year-old female presented following Mohs' extirpation of an aggressive SCC of the nasal dorsum. The skin defect comprised the entire dorsum, as well as portions of both sidewalls, the tip, and the left ala. Structural losses included upper and lower lateral cartilages and a significant portion of the dorsal septum. Lining defects were present bilaterally from the alar margins to the nasal bones. The patient wanted a simple reconstruction, but also wished to resume an active social life. Reconstruction began with removal of the residual pre-existing nasal hump. This, along with lateral osteotomies and infracturing of the nasal bones, significantly decreased the total surface area of the wound. A portion of the remaining septum was mobilized as an anteriorly based L-shaped chondromucoperichondrial flap, the cephalad aspect of which was rotated anteriorly to replace missing dorsal septum. The cephalad border of the cartilage flap was

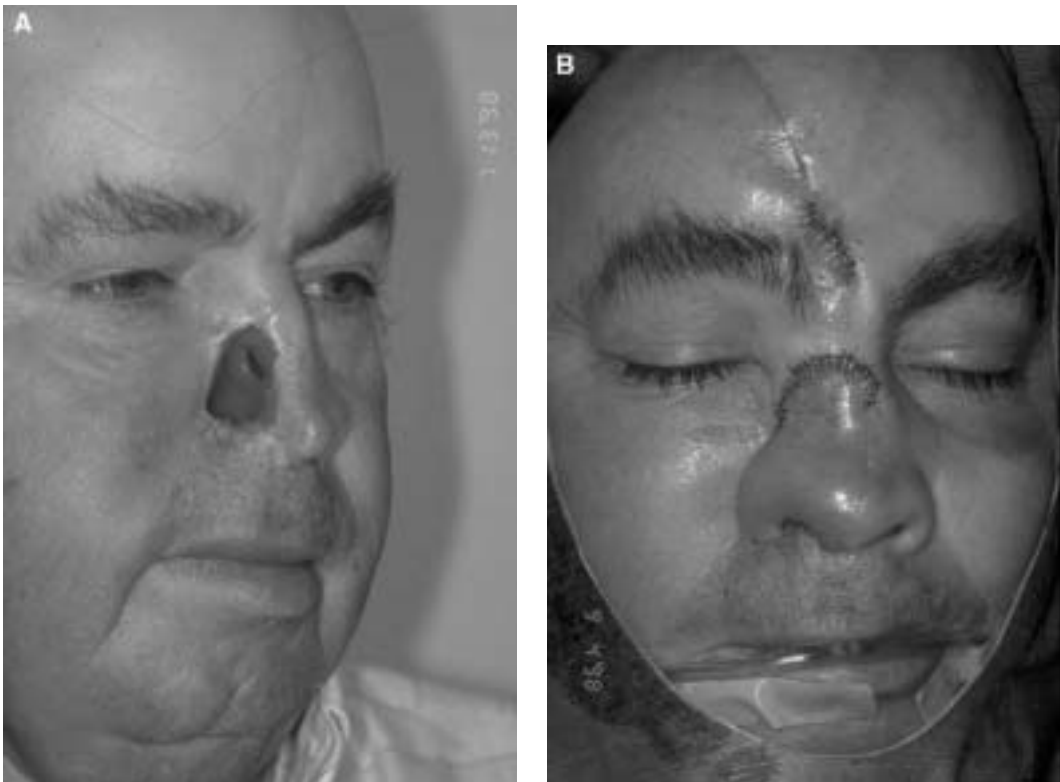

Fig. 9. Delayed reconstruction of a heminasal defect in a radiated field. The patient had undergone excision of a recurrent skin cancer arising in a previous reconstruction. (A) Preoperative frontal view. Note erythematous postradiation changes of right cheek skin. The patient previously had a paramedian forehead flap. (B) Immediately following division and inset of second forehead flap. Lining was supplied with epithelial turnover flaps.

secured to stationary proximal septum with a cartilage step-cut and prolene sutures. An incision was made from the upper aspect of the wound on either side into infraorbital creases, and bilateral cheek advancement flaps were mobilized medially and secured to underlying periosteum. Full-thickness skin grafts were harvested from the postauricular areas and then sutured into the wound to replace all nasal lining. The remainder of the nasal tip skin was excised. A paramedian forehead flap was mobilized and thinned only in its most distal portion, which was intended to resurface the secondarily excised nasal tip skin. The flap then was inset. The nares were packed for several days to ensure good apposition of the intranasal skin grafts to the undersurface of the forehead flap. Three weeks later, the forehead flap was re-elevated as a 3-mm thick bipedicle skin flap, leaving attached the pedicle proximally, and the previously thinned skin distally. Soft tissue was excised from the nasal wound bed as necessary to provide proper contour, and conchal cartilage grafts were placed in the tip and ala. The skin flap then was reinset. Three weeks following the second stage, the flap pedicle was divided. Excess skin and subcutaneous tissue was removed from the distal portion of the flap, and final inset was accomplished. The residual proximal pedicle was excised, and the donor site was closed as a vertical linear wound (Fig. 8).

Case 9

A 55-year-old man presented following extirpation of a recurrent nasal skin cancer. He had previously undergone excision of the original skin cancer, followed by reconstruction with a forehead flap. His entire original reconstruction was excised with the recurrent cancer, leaving him with a heminasal defect. The patient also had received adjuvant radiation to the operative field. Turnover flaps of epithelium bordering the wound provided lining for the secondary reconstruction. Conchal cartilage then was used to provide support for the nasal tip. A second paramedian forehead flap was used to provide skin cover. Three weeks later, the pedicle was divided and the flap inset. Although the entire forehead flap survived, contraction of the nasal lining resulted in stenosis of the right nostril. Complete correction of the stenosis proved to be difficult. Improvement was obtained with a full-thickness skin graft and extended splinting. Additional reconstruction with an ipsilateral nasolabial flap was considered, but was felt to be too risky because the remaining cheek skin was both tight and visibly damaged by radiation. A contralateral nasola-

bial flap was transferred to the alar base, but incomplete correction persists (Fig. 9).

Summary

Nasal reconstruction after skin cancer can be very demanding, especially if the patient's expectations are high. Careful assessment of the defect and thorough preoperative planning are as important to the final result as is the technical execution of the procedure. Often, staged procedures will be required to achieve the optimal result. A successful reconstruction can provide a lifetime of satisfaction for the patient, however, and can be almost equally rewarding for the meticulous surgeon.

References

- [1] Burget GC, Menick FJ. Nasal support and lining: the marriage of beauty and blood supply. *Plast Reconstr Surg* 1989;84:189–203.
- [2] Burget GC, Menick FJ. The subunit principle in nasal reconstruction. *Plast Reconstr Surg* 1985;76:239–47.
- [3] Burget GC. Aesthetic restoration of the nose. *Clin Plast Surg* 1985;12(3):463–80.
- [4] Menick FJ. Aesthetic refinements in use of forehead for nasal reconstruction: the paramedian forehead flap. *Clin Plast Surg* 1990;17(4):607–22.
- [5] Menick FJ. The use of skin grafts for nasal lining. *Clin Plast Surg* 2001;28(2):311–21.
- [6] Menick FJ. A 10-year experience in nasal reconstruction with the three-stage forehead flap. *Plast Reconstr Surg* 2002;109(6):1839–55.
- [7] Burget GC, Menick FJ. Aesthetic reconstruction of the nose. St. Louis (MO): Mosby; 1994.
- [8] Barton Jr FE. Aesthetic aspects of partial nasal reconstruction. *Clin Plast Surg* 1981;8(2):177–91.
- [9] Millard DR. Reconstructive rhinoplasty for the lower half of the nose. *Plast Reconstr Surg* 1974;53(1):133–9.
- [10] Gloster Jr HM. The use of full-thickness skin grafts to repair non-perforating nasal defects. *J Am Acad Dermatol* 2000;42:1041–50.
- [11] Humphreys TR, Goldberg LH, Wiemer DR. Repair of defects of the nasal ala. *Dermatol Surg* 1997;23:335–49.
- [12] Jackson I. Local flaps in head and neck reconstruction. St. Louis (MO): Mosby; 1985.
- [13] Heller N. Subcutaneous pedicle flaps in facial repair. *Ann Plast Surg* 1991;27(5):421–8.
- [14] Zitelli JA. The bilobed flap for nasal reconstruction. *Arch Dermatol* 1989;125:957–9.
- [15] Burget GC. Aesthetic reconstruction of the tip of the nose. *Dermatol Surg* 1995;21:419–29.
- [16] Yanai A, Nagata S, Tanaka H. Reconstruction of the

- columella with bilateral nasolabial flaps. *Plast Reconstr Surg* 1986;77:129–31.
- [17] McCarthy JG, Lorenc ZP, Cutting C, Ratchesky M, et al. The median forehead flap revisited: the blood supply. *Plast Reconstr Surg* 1985;76: 866–9.
- [18] Singh DJ, Bartlett SP. Aesthetic considerations in nasal reconstruction and the role of modified nasal subunits. *Plast Reconstr Surg* 2003;111(2):639–48 [discussion: 649–51].
- [19] Park SS. Reconstruction of nasal defects larger than 1.5 centimeters in diameter. *Laryngoscope* 2000;110: 1241–50.